

## Incidence of perineural invasion in prostate adenocarcinoma: Rural Kenyan population experience

Nzioka A<sup>1</sup>, Onyuma T<sup>2</sup>, Gakinya S<sup>3</sup>

<sup>1</sup>Department of Pathology,  
School of Medicine,  
Kenyatta University

<sup>2</sup>Social Service League,  
The MP Shah Hospital,  
Nairobi

<sup>3</sup>Department of Pathology,  
Aga Khan University  
Hospital, Nairobi

### Corresponding author:

Dr. A. Nzioka, Department  
of Pathology, School  
of Medicine, Kenyatta  
University, P. O. Box  
43844-00100, Nairobi,  
Kenya. Email: [kancent@  
yahoo.com](mailto:kancent@yahoo.com)

### Abstract

**Introduction:** Prostate cancer appears to be more aggressive amongst patients of African descent, a condition which could be associated with the presence of perineural invasion and higher Gleason scores of the cancer.

**Objective:** This study evaluated the incidence of perineural invasion in previously diagnosed prostate cancer cases in a rural hospital which receive numerous cases of prostate cancer annually.

**Setting:** This was a retrospective cross sectional study conducted at a busy mission referral hospital in rural Kenya. A total of 151 cases were included in the study. Patients' biodata was retrieved from the laboratory information system. Hematoxylin and eosin stained slides of previously diagnosed cases of prostate cancer over a period of one year (January 2012 to December 2012) were retrieved. These slides were microscopically examined for perineural invasion and the tumour grade determined using Gleason scoring.

**Results:** Specimens from 151 patients were examined for perineural invasion. The patients' ages ranged from 46 to 93, mean age 73.77 (SD 9.474). Tumours in high grade category were 75.5% of the total number of cases while the rest (24.5%) were intermediate/low grade tumours. Out of these, 55.6% of the biopsies had perineural invasion. There was no significant relationship between the patients' age and the grade of tumour. Data on comparison of the cancers with perineural invasion and those without perineural invasion for grade demonstrated significant association between the tumour grade and the presence of perineural invasion ( $p \leq 0.0001$ ).

**Key words:** Prostate cancer, Gleason score, Perineural invasion, Rural Kenyan African population

### Introduction

Prostate cancer presents a diagnostic and management challenge in rural settings in

Africa. It has been frequently reported that the disease appears to be more aggressive amongst patients of African descent [1,2]. Reports indicate presence of perineural invasion in prostate biopsy specimens is associated with biologically aggressive disease presentation and higher Gleason scores [3]. Other reports suggested that innervations by the autonomic nervous system plays a role in the development and the maturation of the prostate gland [4] and that the perineural migration of malignant prostate cancer cells was more than just a mechanical phenomenon of cell movement through a plane of low resistance and that there were linking interactions between the prostate epithelial cells and the nerves with perineural tumour spread [5].

Reports on perineural invasion in prostate cancer biopsy specimens have indicated that the phenomenon may be very common [3, 6]. With this background, we set out to investigate the prevalence of perineural invasion previously diagnosed prostate cancer biopsy specimens among patients in a rural African population in Kenya.

### Materials and Methods

This was a retrospective study conducted at a busy rural referral hospital in Central Kenya between January 2012 and December 2012. Demographic data was retrospectively reviewed. In short, previous diagnostic hematoxyline-eosin stained slides from previously diagnosed prostate cancer biopsy specimens, going back for a period of twelve months (January 2012 and December 2012) were retrieved and examined for adenocarcinoma. A total of 151 specimens slides were retrieved and examined under a microscope classified by Gleason score assignment.

Stratification of the adenocarcinomas into low/intermediate grade and high grade was done where a pathologic Gleason score of 4+3 or 8 and above was considered high grade. Comparison of

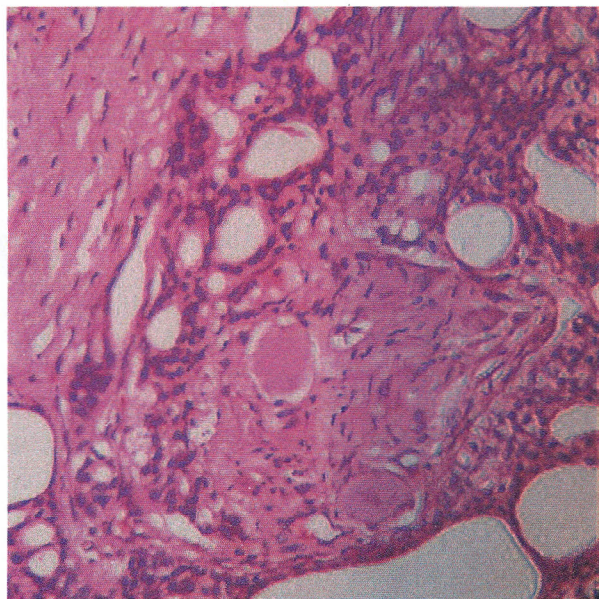
the cancers with perineural invasion and those without perineural invasion for grade was done [7, 8].

Only biopsies with adenocarcinoma within which a Gleason score could be unequivocally assigned were included. A pathologic Gleason score of 8 and above or 4+3 was considered high grade [9]. Lower scores were considered intermediate or low grade. The main outcome was perineural invasion which was defined as the presence of malignant prostate epithelial cells in, around and through the nerves.

Collection of data was done in Microsoft Excel spreadsheets and analysis was performed using SPSS version 13. The main outcome was perineural invasion. Comparison between groups was performed using the chi-square test. Analysis for the strength of association was performed using logistic regression. Ethical approval was granted by the institutional review board of the hospital.

## Results

Specimens from 151 patients were examined for perineural invasion. This was defined as the presence of tumour cells in, around and through the nerve fibers. The patients' ages ranged from 46 to 93, mean age 73.77 (SD 9.474). Tumours in high grade category were 75.5% of the total while the rest (24.5%) were intermediate/low grade tumours. Out of these, 55.6% of the biopsies had perineural invasion. There was no significant relationship between the patients' age and the grade of tumour.



**Figure 1:** Perineural invasion

Data on comparison of the cancers with perineural invasion and those without perineural invasion for grade (Table 1) demonstrated significant association between the tumour grade and the presence of perineural invasion ( $X^2 22.96$ ,  $df = 1$ ,  $p < 0.0001$ ).

**Table 1:** Comparison of tumour grade with perineural invasion

Tumour grade	Perineural invasion		Total
	Absent	Present	
Low and Intermediate	29(78.4%)	8 (21.6%)	37(24.5%)
High grade*	38(33.3%)	76(66.7%)	114 (75.5%)
Total	67(44.4%)	84(55.6%)	151 (100%)

\*High grade: Gleason 8 and above including 4+3

Logistic regression was performed to assess this association and it was found that there was a statistically significant increase in the risk of finding perineural invasion in tumours categorized as high grade with an odds ratio of 7.25 95% CI [3.025 – 17.37]. In addition, when a Gleason score of 4+3 is classified in the low/intermediate category, the association remained statistically significant ( $X^2 16.18$   $df = 1$ ,  $p \leq 0.0001$ ) and the odds ratio was 3.94 95% CI (1.99-7.80).

## Discussion

Our study demonstrated that perineural invasion was as high as 55.6% among prostate cancer patients. Related previous studies on the same area reported more or less similar results [10]. Perineural invasion was associated with aggressive tumours and extensive disease spread at radical prostatectomy [3,11,12]. Given that the disease has also been reported to be more aggressive amongst patients of African descent [1], it was interesting to investigate this in a rural African setup.

When compared to those without high grade tumours, according to our data, there was a 7 fold risk (odds) of finding perineural invasion in biopsies with high grade tumours. This finding is consistent with what has been published in the literature linking perineural invasion to aggressive tumours. Vargas and others in this study correlated perineural invasion in prostate needle biopsy specimens with extraprostatic extension at resection [3].

Studies conducted elsewhere on the biological significance of the finding of perineural invasion indicated that the cancer cells found within the areas of a tumour with perineural invasion tend to show increased proliferation than the areas without perineural invasion [6], the findings which remained significant even after adjustment of the Gleason score, tumour size and the pathological stage. It was also demonstrated that increased expression of the Heregulin (HRG) and macrophage migration inhibitory factor (MIF) in cancer cells, and the receptors CD74 and epidermal growth factor receptor (EGFR) in both cancer cells and nerves, cementing the hypothesis of tumour cell-nerve interaction. In addition, "benign perineural involvement" has been reported in the perineural space by benign atrophic glands and this could potentially have been a confounder [13].

Limited by the lack of immunostaining, we relied on hematoxylin and eosin stained slides to directly identify perineural invasion. In addition, "benign perineural involvement" has been reported in the perineural space by benign atrophic glands and this could potentially have been a confounder [13].

## Conclusion

Perineural invasion is a common finding in prostatic adenocarcinoma in rural Africa populations. The high grade tumours are more likely to show perineural invasion. The finding of perineural invasion is therefore an important predictor of tumour biology in prostatic adenocarcinoma.

## References

1. Jones J. African-Americans and prostate cancer: Why the discrepancies? *J National Cancer Institute*. 2001; **93**(5):342-344.
2. Su LJ, Arab L, Steck SE, Fontham ET, Schroeder JC, *et al*. Obesity and prostate cancer aggressiveness among African and Caucasian Americans in a population-based study. *Cancer Epid Biomarkers Prev*. 2011; **20**(5):844-853.
3. Vargas SO, Jiroutek M, Welch WR, Nucci MR, D'Amico AV and Renshaw AA. Perineural invasion in prostate needle biopsy specimens. Correlation with extraprostatic extension at resection. *Am J Clin Pathol*. 1999; **111**(2):223-228.
4. McVary KT, McKenna KE and Lee C. Prostate innervation. *Prostate* 1998;**8** (Suppl.): 2-13.
5. Cornell RJ, Rowley D, Wheeler T, Ali N and Ayala G. Neuroepithelial interactions in prostate cancer are enhanced in the presence of prostatic stroma. *Urology*. 2003; **61**(4):870-875.
6. Fromont G, Godet J, Pires C, Yacoub M, Dore B and Irani J. Biological significance of perineural invasion (PNI) in prostate cancer. *The Prostate*. 2012;**72**(5):542-548.
7. Humphrey PA. Gleason grading and prognostic factors in carcinoma of the prostate. *Mod Pathol*. 2004; **17**(3):292-306.
8. Delahunt B, Miller RJ, Srigley JR, Evans AJ and Samaratunga H. Gleason grading: past, present and future. *Histopathology*. 2012; **60**(1):75-86.
9. Stark JR, Perner S, Stampfer MJ, Sinnott JA, Finn S, *et al*. Gleason score and lethal prostate cancer: does 3 + 4 = 4 + 3? *J Clin Oncol*. 2009; **27**(21):3459-3464.
10. Liebig C, Ayala G, Wilks JA, Berger DH and Albo D. Perineural invasion in cancer: a review of the literature. *Cancer*. 2009; **115**(15):3379-3391.
11. Harnden P, Shelley MD, Clements H, Coles B, Tyndale-Biscoe RS, *et al*. The prognostic significance of perineural invasion in prostatic cancer biopsies: a systematic review. *Cancer*. 2007;**109**(1):13-24.
12. Ozcan F. Correlation of perineural invasion on radical prostatectomy specimens with other pathologic prognostic factors and PSA failure. *Eur Urol*. 2001;**40**(3):308-312.
13. Ali T and Epstein JI. Perineural involvement by benign prostatic glands on needle biopsy. *Am J Surg Pathol*. 2005;**29**(9):1159-1163.