

# In Vivo Toxicological and Histopathological Effects of Aflatoxin B<sub>1</sub> Exposure and Related Risk

Peter Juma Ochieng<sup>1</sup>, Daniel Okun<sup>2,1</sup>, Isac Mugenya<sup>3</sup>, N.J Njagi<sup>4,1</sup>, Mugai John<sup>5,3</sup>

<sup>1</sup> Kenyatta University, Department of Biochemistry & Biotechnology,  
Thika Road, Nairobi P.O.Box 43844-00100, Kenya

<sup>2</sup> Kenya Bureau of Standards, Mycotoxin Laboratory  
Mombasa Road, Nairobi P.O.Box 54974-00200, Kenya

<sup>3</sup> Government Chemist, Toxicology Section  
Upper Hill 10<sup>th</sup> Street, Nairobi 20723-00200, Kenya

*twinsjuma@gmail.com (Peter Juma Ochieng)*

## Abstract

Aflatoxin B<sub>1</sub> are toxic metabolites of *Aspergillus flavus* and *Aspergillus parasiticus* which usually contaminant foods such peanuts, corn, and other grains as well as animal feeds resulting into intoxication. Studies have been conducted to elucidated the mechanism of AFB<sub>1</sub> toxicity however, there is still a challenge explore the risk associated with AFB<sub>1</sub>. Therefore, the main objective of this research was to performed toxicological and histopathological analysis of aflatoxin B<sub>1</sub> and related risk. Populations of mice were treated with ascending dosed of 3mg/Kg, 6mg/Kg, 9mg/Kg and 12mg/Kg of AFB<sub>1</sub>. the LD<sub>50</sub> was then recorded, the liver biopsy from scarified and dead mice were screened for analysis of distribution of AFB<sub>1</sub>. Enzyme transaminases activity and total bilirubin content was then analysed by spectrometry, histology was then on performed on biopsy lastly; prothrombin time analysis conducted to assess the effect of AFB<sub>1</sub> on blood clotting factors. From the results death occurred within 48 hours for most mice treated with doses of 9mg/Kg and 12mg/Kg, biochemical test showed significant increase transaminases (ALT, AST and AP) activity with fluctuation of bilirubin content with gradual increases in prothrombin time (PTT). Liver biopsy showed bile duct proliferation, vacuolation of hepatocytes, enlargement of hepatic cells, fatty infiltration, necrosis, hemorrhage, and apoptosis. We concluded that prolonged consumption of AFB<sub>1</sub> contaminated feed or food at dose range of 3-6 mg/Kg may result to development of hepatocellular carcinoma while 9-12mg/Kg AFB<sub>1</sub> may lead to server liver injury. Thus there are higher risk of AFB<sub>1</sub> to induce hepatocellular carcinoma (HCC), mutagenic and Immune-suppression to both humans and animals.

**Keywords:** AFB<sub>1</sub>, LD<sub>50</sub>, PTT

## Presenting Author's biography



Peter Juma Ochieng. MSc. Computational science ( Bioinformatics) IPB-University, BSc.(Forensic Science) Kenyatta University ; NHD (Forensic Fingerprint Analysis & Toxicology) Hawk Eyes Institute of Technology; Member of Institute of Certified Forensic Investigation Professional (IICFIP); American Academy of Forensic Science (AAFS) & Kenyatta University Forensic Science Association (KUFSA)

## Introduction

In the recent years, much effort and investment have been channeled towards food security, food safety and epidemiology mitigation by developing countries. In 2005 WHO epidemiology report shows that in Asia, Africa and South America the prevalence of cancer and infant mortality have skewed up by 60% the past two decades [7][16][18]. The susceptible individuals are families that feed on corn and other cereals as staple food, studies have postulated that this might have been as result of exposure to food contaminated by aflatoxins [2][19]. An aflatoxin outbreak initially reported in United Kingdom in 1962 it affected poultry and it was named turkey "X" disease [3]. Outbreaks of acute aflatoxicosis are a recurring public health problem throughout the world [1, 8, 13,14]. The effects of aflatoxins on humans, as with animals, are dependent upon dosage and duration of exposure [21]. Acute exposure can result in aflatoxicosis, which manifests as severe, acute hepatotoxicity with a case fatality rate of approximately 25% [11][22]. Early symptoms of hepatotoxicity from aflatoxicosis can manifest as anorexia, malaise, and low-grade fever. Acute high level exposure can progress to potentially lethal hepatitis with vomiting, abdominal pain, jaundice, fulminant hepatic failure, and death [10]. The route cause of hepatocellular carcinoma (HCC) is due to chronic exposure to AFB<sub>1</sub> based on previous studies. Moreover, it is generally associated with hepatitis B virus or other risk factors [5, 9, 10, 11,]. In 1976, the International Agency for Research on Cancer (IARC) first recognized aflatoxins as carcinogenic and has subsequently reaffirmed naturally occurring mixtures of aflatoxins and aflatoxin B<sub>1</sub> as Group 1 carcinogens (carcinogenic to humans) [8]. Additional effects of chronic exposure have not been widely studied but are thought to include immunologic suppression, impaired growth, and nutritional interference [10, 11,12]. Therefore, objective of this research is to perform in vivo toxicological and histopathological effects of AFB<sub>1</sub>. To achieve this we (i) performed LD<sub>50</sub> test to determine lethal dose of AFB<sub>1</sub> (ii) evaluate the distribution of AFB<sub>1</sub> in liver biopsy (iii) perform histology to examine the cytopathology. Lastly perform biochemical analysis to test the (iv) the effect of AFB<sub>1</sub> on the enzyme activity, bilirubin content and blood clotting factor.

## Materials and Method

This research was conducted in Histopathology and Biochemistry laboratory (Department of Human Pathology) Faculty of Medicine and department of Biochemistry and Biotechnology respectively at Kenyatta University, Chromatographic and Purified AFB<sub>1</sub> sample was prepared in the laboratories of Kenya Breuer of standards and Government Chemist Nairobi Kenya.

A population of 280 white papsy mice was bred at biochemistry animal house; the mice were supplied ad libitum and maintained in colony cage at ambient room condition for 3 months to achieve the desired population and size. The animals were sorted into males, female and winners (young mice). For AFB<sub>1</sub> stock solution preparation, 1g of crystal AFB<sub>1</sub> was dissolved into 1000ml dimethylformamide. For efficacy evaluation we prepared lethal doses of 3mg/Kg, 6mg/Kg, 9mg/Kg and 12mg/Kg.

### LD<sub>50</sub> Test

In this analysis 200 mixed population was used the mice were divided into five groups consisting of 40 mice each labeled A, B, C D and E respectively. Serial ascending dose of 3mg/Kg, 6mg/Kg, 9mg/Kg and 12mg/Kg of pure AFB<sub>1</sub> was administered by injected intraperitoneally to group A,B,C and D respectively. Nonetheless, group E were treated with only 0.1 ml of dimethylformamide (DMF). Eq.1 was used to calculate the amount of AFB<sub>1</sub> administer to each mouse.

$$\text{AFB1 administered(ml)} = \frac{\text{Concentration of AFB1 (mg/l)}}{\text{Body Weight of mouse(Kg)}} \quad (1)$$

The LD<sub>50</sub> was the estimated using the Weil method [3] the toxic dose range of the four dosed was recorded base on the number of mice died.

### Histology

After LD<sub>50</sub> test, dead mice were autopsied and affected organs were screened using hand held UV lamp at a wavelength of 420nm. The affected biopsy were removed and fixed in 10 % formol saline (Helly's fluid), embedded in paraffin wax, microtomed (sectioned) at 5 μ and stained with haematoxylin and eosin. For some sections, we used additional stain in this case Masson's trichrome stain and methyl-green pyronin. Others liver biopsies were stained using oil red "O".

### Biochemical analysis

Population of fifty mice were breed at Kenyatta university zoology laboratory, the mice were the selected randomly and divided into 5 groups with 10 mice in each then feed and water were offered *ad lib*. The first group was given chromatographic purified AFB<sub>1</sub> as single dose of 9 mg AFB<sub>1</sub> per Kg body weight of mice. The second groups were maintained for 14 days again treated with AFB<sub>1</sub>. The third group was placebo (control) and maintained on AFB<sub>1</sub> free feed. In addition, five mice were randomly selected from each group and bleed them by cardiac puncture euthanatized and necropsies daily during the first 7 days. After 2 week serum of each mice were separated and used for estimation of AP according to Kind and King 1954 , transeaminase (ALT and AST ) according to Reitman and Frankel [3] and bilirubin content according to Jendrassik and Gorf [3]. Enzyme kit was used for testing AP, AST, ALT and for bilirubin content we used stock solution of reference 605-11(sigma) to prepare the test solution.

### Prothrobin Time Analysis (PTT)

To determined prothrobin time, a population of 30 mice was used from this a set of 12 mice with estimated average weight of 30g, fed for one week *ad libitum* on the feed treated by single dose of 12 mg/Kg of AFB<sub>1</sub>. The other three groups of 6 similar male mice were injected intraperitoneally with ascending doses of 6 mg/Kg, 9mg/kg and 12 mg/Kg AFB<sub>1</sub> (Hopkins & Williams, Essex, England). Another group of mice was kept as placebo on the uncontaminated diet. The blood clotting times of the test animals and their controls were determined using the thrombotest reagent according to Owren [3].

### Results

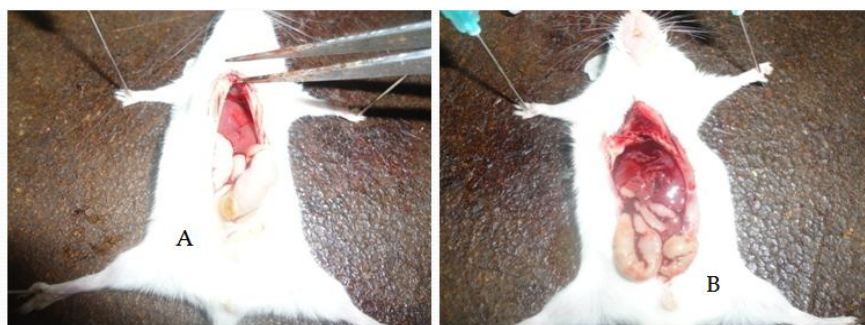


Fig.1 Internal hemorrhages caused by AFB<sub>1</sub> intoxication (A) normal mice with no internal hemorrhage (B) AFB<sub>1</sub> treated mice show internal hemorrhage

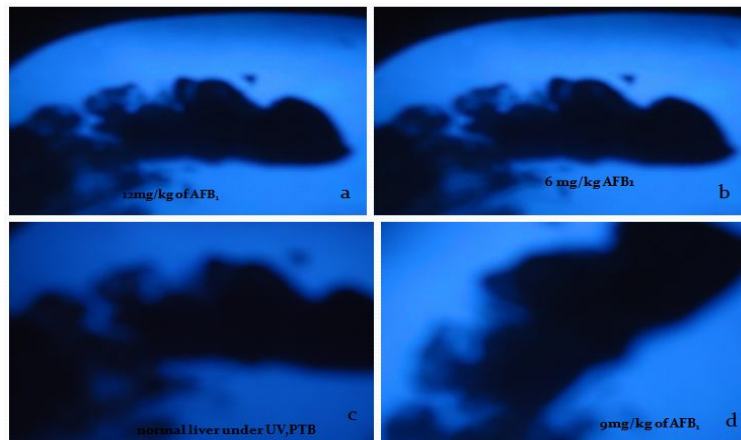


Fig. 2 shows the distribution of AFB1 in the liver biopsy: (a) at 12mg/Kg medial distribution of AFB1 (b) at 6 mg/Kg marginal distribution (c) normal liver biopsy AFB1 free (d) 9mg/Kg zonal distribution of AFB1.

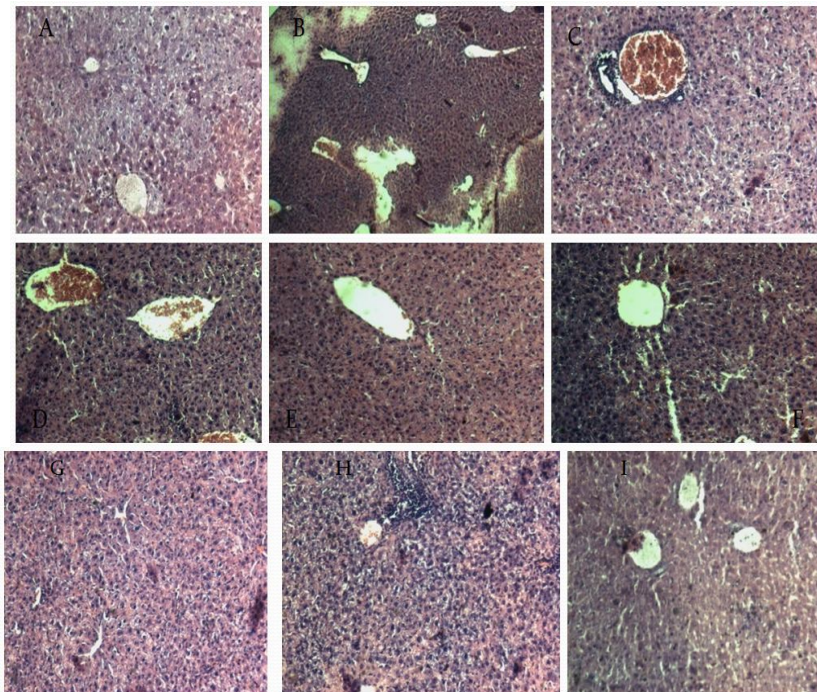


Fig 3 Histopathological changes in liver Biopsy

Fig.3. Shows liver biopsy of AFB1 treated mice : (A) Vacuolar degeneration (H.&E. stain, 10x10); (B) Half moon or shrunk nuclei (arrows) in addition to vacuolar degeneration and glycogen infiltration (10x10); (C) Liver of mice sacrificed 48 hours after single dose of aflatoxin B1, showing early periportal zone of necrosis. H. and E. X 40. (D) Liver of mice killed 72 hours after single dose of AFB1, showing early biliary proliferation. H. and E, X 250. (E) Liver of male mice sacrificed after 72 hours after showing fat-laden parenchymal cells adjacent to zone of necrosis. Oil red O. X 100. (F) Liver of mice showing well developed biliary proliferation. H. and P, X 100. (G) Biliary proliferation. H. and E. X 250. (H) Extensive biliary proliferation. H. and E. X 100.(I ) early development of cirrhosis cholangio fibrosis, a small hyperplastic nodule large hyperchromatic parenchymal cell. H. and E. x 400

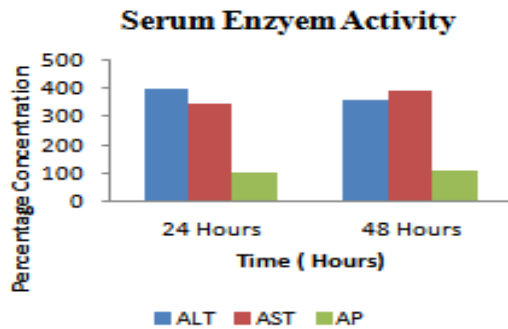


Fig. 4

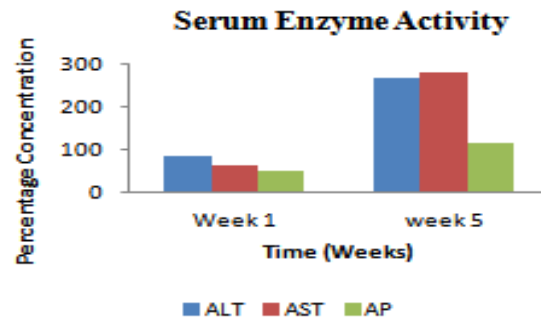


Fig. 5

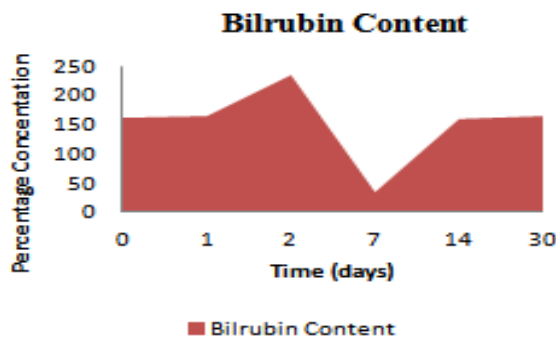


Fig. 6

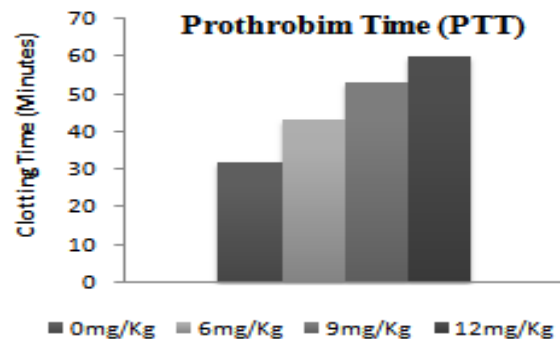


Fig. 7

## Discussion

The LD<sub>50</sub> experiment showed that, most of the mice died in 2-4 days after treatment with AFB<sub>1</sub>. There was no death reported within the initial 24 hours or after 7 days. In addition, no deaths were reported in the placebo animals given DMF alone. The LD<sub>50</sub> for male mice with estimated weight of 30g in this study proved similar to that of the smaller mice. This was evidenced by clinical symptoms in the initial 2-3 days the mice lost appeared weak (poor condition) and lost weight. In addition those mice that died during this time there was little stomach content in their gastrointestinal tract (GIT). However, on the 3-4 days, the survived mice started gaining weight and appeared to eating and drinking normally. Those which died at a later time failed to show any weight gain while others showed symptoms of jaundice after four or five days. At autopsy, the livers of male mice during and some on early stages were pale pink in colour with an accentuated lobular pattern and occasional macroscopic areas of haemorrhage (see fig.3 slide H and G). On the other hand, the livers of female mice were pale yellow in colour. The lungs were congested and there were occasional haemorrhagic, bilateral adrenal haemorrhages (see fig.1). After one week, autopsied mice showed ascites and oedema of the omentum alimentary tract was filled blood and malaena faeces. There was no macroscopic ulceration seen observed. For placebo mice, there were no macroscopic alterations in the livers and pathology on other organs.



Histopathological investigation revealed that the liver is the target organ for AFB<sub>1</sub> and Ingestion of aflatoxin B<sub>1</sub> contaminated food, is capable of inducing acute intoxication, aflatoxicosis that is believed to be candidate agent to induce hepatoma. It was postulated that AFB<sub>1</sub> might have been converted into its epoxide which is acts as the derivative to produces DNA adducts hence causing flaking of DNA strand leading to point mutation This condition, results into active process of cellular self-destruction leading to apoptosis. Our investigation on AFB<sub>1</sub> treated mice showed hepatic damage. The morphological changes of hepatocytes in AFB<sub>1</sub> treated mice was described by Saraste and Pulkki where there was contraction in cell volume, condensation of the nucleus and the nucleus fragmentation. Finally, the cell itself fragments to form apoptotic bodies, which are engulfed nearby phagocytes. Similarly, according to Shen *et al.*, findings *in vivo* evidence showed that AFB<sub>1</sub> can cause lipid peroxidation in rat liver [22]. The authors suggested that oxidative damage caused by AFB<sub>1</sub> might be one of the underlining mechanisms for AFB<sub>1</sub> induced cell injury and DNA damage, which eventually lead to tumorigenesis [24].

Further, the histopathological findings showed that AFB<sub>1</sub> induced hepatotoxic effects, in the form of degenerative and necrobiotic changes that were evidenced by vacuolar degeneration as well as appearance of minute foci of necrosis (see fig. 3. E and F). It also induced apoptosis of the hepatocytes in the most of the mice exposed to 12mg/Kg AFB<sub>1</sub>. From this research we discovered that only case showed preneoplastic foci (see fig.3. A). In this senario hepatocyte damage was evidenced by condensation of nuclear chromatin by defined masses that margined against nuclear membrane as well as formation of half moon shaped or round dense nuclear remnants. The cells were shrinkage and the cytoplasm was condensed. In addition, the appearance of many apoptotic bodies might have been engulfed by adjacent kupffer cells. In summary, we used all these features to describe the morphological criteria to evaluate AFB<sub>1</sub> effects liver biopsy.

The Enzyme activity in mice showed that within 24 hours of treatment with ascending doses of AFB<sub>1</sub> (9mg/Kg, 6mg/Kg and 12mg/Kg AFB<sub>1</sub> body weight) the level of bilirubin content and activity of AST, ALT and AP increased by significantly by 162%, 398%, 342% and 102% respectively. The maximum levels of AFB<sub>1</sub> effects were achieved within 48hours with an increase in concentration bilirubin content and AST at 232% and 359% respectively. Three days after, ALT level were 392% while the levels of AP 113%, however with the decrease in bilirubin level and subsequent decrease in serum activity approaching at relatively significant minimum threshold level. After one week, the mice were treated again with AFB<sub>1</sub> and the enzyme activity of ALT, AST and AP recorded 67%, 65% 55% and 35% higher than the initial day (day 0). We noticed that at the end of one week after treating mice with AFB<sub>1</sub> the activity of all the enzymes were normalized and the bilirubin activity recorded the same activity levels of 37% slightly higher than the placebo sera level. The raise in the activity of sera transminases (ALT, AST and AP) and bilirubin content treated with AFB<sub>1</sub> induced acute liver injury. After one month, the enzyme activity and bilirubin content increased gradually to 265%, 269%, 115% and 165%. Based on this we concluded that mice treated by AFB<sub>1</sub> the serum activities of those enzymes tremendously increased to significantly higher levels and later remained higher[23][25].

Previous studies of acute effects of aflatoxin B<sub>1</sub> in dogs by Newberne, Russo & Wogan [16] observed occasional haemorrhage in the gastrointestinal tract, also found that the blood clotting time was prolonged by a factor of 10. In a review by Schoental [20], emphasis was placed on the need for studies on the anticoagulant property (amongst other pharmacological properties) of aflatoxin in doses, which are not acutely toxic [20]. The prothrombin time analysis in this research show that the blood of mice treated with AFB<sub>1</sub> showed prolonged blood clotting time at different doses this was due to effect of AFB<sub>1</sub> as anticoagulants activity (see graph fig.7). The thrombo test technique the phyliogram showed effect of AFB<sub>1</sub> on blood clotting factors especially factors II (prothrombin), VII (proconvertin), IX (plasma

thromboplastin component) and X (Stuart-Prower factor) were likely affected by AFB<sub>1</sub>. According to Asao et al. (1963) evidence showed that aflatoxin B1 is a coumarin type compound, having a central 5-methoxycoumarin moiety that interfere with the activity of blood clotting proteins.

### **Conclusion**

In conclusion, in this experiment, the mice treated with AFB<sub>1</sub> showed clinical symptoms of aflatoxicosis at dose range of 3-6 mg/Kg and those exposed to higher dose range of 9-12 mg/Kg died. However, those that survive this dose experienced more severe liver damage than the dead mice. This was evidenced by increasing the transaminases activities, bilirubin contents and histopathology change of liver biopsy evidenced by biliary proliferation and apoptosis. In addition, we discovered that AFB<sub>1</sub> also interfere with blood clotting factors II, VII, IX and X. This was again evidenced by prolong prothrombin time and internal hemorrhage. In summary we deduced that there is higher chances of AFB<sub>1</sub> induce massive damage hepatocyte resulting into liver dysfunction associated with biochemical disturbances in oxidant or antioxidant balance system which interlinked pathogenic networks of the AFB<sub>1</sub> toxicity. Thus of ingestion of AFB<sub>1</sub> contaminated food or feed calls for urgent clinical measures before servier of liver, which may result to death. Our future work is conduct research to explore clinical measures to diagnose of aflatoxicoses and afltoxicosis by regulating apoptosis with potentially excellent target for diagnosis and therapeutic intervention in AFB<sub>1</sub> induced liver dysfunction.

### **Acknowledgement**

We express our sincere gratitude to Department of Human Pathology faculty of Medicine and Department of Biochemistry and Biotechnology, School of Pure and Applied Science, Kenyatta University for the research facilities and equipments. We also extent our warm appreciation to members of Mycotoxin Laboratory, Kenya Breuer of Standards for their great work on isolation of AFB<sub>1</sub> sample. Finally, we give thanks to the Government Chemist of Kenya for providing us facilities and pure AFB<sub>1</sub>.

### **References**

- [1] Azziz-Baumgartner, E., K. Lindblade, et al. (2005). "Case Control Study of an Acute Aflatoxicosis Outbreak-Kenya 2004." *Environ Health Perspect.*
- [2] Bankole, S. A. and O. O. Mabekoje (2004). "Occurrence of aflatoxins and fumonisins in preharvest maize from south-western Nigeria." *Food Addit Contam*\_21(3): 251-5.
- [3] Blount, W. (1961). "Turkey "X" disease." *J Br Turk Fed*\_9: 52-54.
- [4] Bolton, M. G., A. Munoz, et al. (1993). "Transient intervention with oltipraz protects against aflatoxin-induced hepatic tumorigenesis." *Cancer Res* 53(15): 3499-504.
- [5] Brown, R., Z. Chen, et al. (1999). "Advances in the development of host resistance in corn to aflatoxin contamination by *Aspergillus flavus*." *Phytopathology* 89: 113-117.
- [6] CAST (2003). *Mycotoxins: Risks in plant, animal, and human systems*. Ames, Iowa, USA, Council for Agricultural Science and Technology: 199.

- [7] CDC (2004). Outbreak of aflatoxin poisoning eastern and central provinces, Kenya January-July 2004 MMWR Morb Mortal Wkly Rep 53(34): 790-3.
- [8] CDC (2005). Aflatoxicosis Outbreak, Kenya - 2005: Report to the Kenya Ministry of Health.
- [9] Chen, S. Y., C. J. Chen, et al. (2001). "Association of aflatoxin B(1)-albumin adduct levels with hepatitis B surface antigen status among adolescents in Taiwan." *Cancer Epidemiol Biomarkers Prev* 10(11): 1223-6.
- [10] Cotty, P. J. and D. Bhatnagar (1994). "Variability among atoxigenic *Aspergillus flavus* strains in ability to prevent aflatoxin contamination and production of aflatoxin biosynthetic pathway enzymes." *Appl Environ Microbiol* 60(7): 2248-51.
- [11] Cullen, J. M. and P. M. Newberne (1994). Acute Hepatotoxicity of Aflatoxins. *The Toxicology of Aflatoxins: Human Health, Veterinary, and Agricultural Significance*. D. L. Eaton and J. D. Groopman. San Diego, CA, Academic Press, Inc.: 3-26.
- [12] Delmulle, B. S., S. M. De Saeger, et al. (2005). "Development of an immunoassay-based lateral flow dipstick for the rapid detection of aflatoxin B1 in pig feed." *J Agric Food Chem* 53(9): 3364-8.
- [13] Eaton, D. L. and J. D. Groopman (1994). *The Toxicology of Aflatoxins: Human Health, Veterinary, and Agricultural Significance*. San Diego, CA, Academic Press, INC.
- [14] Fung, F. and R. F. Clark (2004). "Health effects of mycotoxins: a toxicological overview." *J Toxicol Clin Toxicol* 42(2): 217-34.
- [15] Gong, Y. Y., K. Cardwell, et al. (2002). "Dietary aflatoxin exposure and impaired growth in young children from Benin and Togo: cross sectional study." *Bmj* 325(7354): 20-1.
- [16] Wu, F. & Tritscher, A. (2011). Aflatoxins a global public health problem: Aflatoxins health impact Jan2011. <http://www.argriskmanagementform.org/farm/site/agrisites/agrimntform>. Aflatoxin-public health issue pdf, 1-18.
- [17] Thrasher, J.D. (2012). Aflatoxicosis in animals. *Aflatoxins and Health*, [www.alphaboostjuice.com/AFLATOXICOSIS IN ANIMALS.pdf](http://www.alphaboostjuice.com/AFLATOXICOSIS%20IN%20ANIMALS.pdf).
- [18] USAID. (2012). Aflatoxin: A Synthesis of the Research in Health, Agriculture and Trade. *Feed the Future: The Office of Regional Economic Integration USAID East Africa Regional Mission Nairobi, Kenya*, [www.eastafrica.usaid.gov](http://www.eastafrica.usaid.gov) Research in Health Agriculture and Trade/pdf, 10-15
- [19] Wu, F., et al. (2011). *The Health economics of aflatoxins: Global burden of disease Aflacontrol Working Paper 4 February International Food Policy Research Institute. 2033 K Street, NW Washington, DC 20006-1002 USA*, 1-16.
- [20] Lopez, C., et al. (2002). Aflatoxin B1 in human serum: Aflatoxin B1 content in patients with hepatic diseases. *Medicina (Buenos Aires)*, 313-316.
- [21] Otsuki, T., Wilson, J. S., & Sewadeh, M. (2002). A Race to the Top? A Case Study of Food Safety Standards and African Exports. *Development Research Group (DECRG), World Bank, 1818 H Street NW, Washington DC 20433 USA. 1424\_wps 2563.pdf*
- [22] Guengerich, F. P., et al. (1998). Activation and detoxication of aflatoxin B1. *Mutation Research*, 402, 121-128.
- [23] Stewart, R. K., Serabjit-Singh, C. J., & Massey, T. E. (1996). Glutathione S-transferase catalyzed conjugation of bioactivated aflatoxin B1 in rabbit lung and liver. *Toxicology and Applied Pharmacology*, 140, 499-507.



- [24] Liu, Y., & Wu, F. (2010). Global Burden of Aflatoxin-Induced Hepatocellular Carcinoma: A Risk Assessment. *Environmental Health Perspectives*, 118, 818-824
- [25] Fapohunda, S. O., et al. (2007). Enzyme-related aflatoxin production in vital organs of rats fed with *Aspergillus* species- inoculated rat chow. *Journal of Biology and Environmental Science*, 1(1), 1 41.