

## In Vivo Safety of Aqueous Extracts of *Maytemus putterlickoides*, *Senna spectabilis* and *Olinia usambarensis* on Mice Models

Mugweru FG\*, Nyamai DW, Arika WM, Mworja JK, Ngugi MP, Njagi ENM and Ngeranwa JJN

Department of Biochemistry and Biotechnology, School of Pure and Applied Sciences, Kenyatta University, Kenya

### Abstract

Plant products are used as the primary health care in developing countries due to their availability and affordability compared to conventional methods. It is estimated that more than 80% of the world's population use herbal preparations in the management and treatment of diseases. Herbal products are now readily available in supermarkets and drug stores. The therapeutic value of these herbal products is believed to be due to the presence of bioactive elements present in the plant parts. Toxicity studies should, however be carried to ascertain the safety of the herbal preparation. In this study, safety studies were carried out through biochemical assays, histopathology and hematological tests. The plant extracts led to changes in body weight, hematological and histopathological changes like increase in lymphocyte number. High dose of orally administered *Olinia usambarensis* also caused microcytic hypochromic anemia. *Senna spectabilis* and *Olinia usambarensis* revealed intense infiltration of inflammatory cells causing necrosis and loss of cellular details of the kidney. This study will enhance understanding of the safety of ethno-medical materials in the management of diarrhea caused by bacterial pathogens.

**Keywords:** *Senna spectabilis*; Haematology; *Olinia usambarensis*; Histopathology

### Introduction

Plants have been a source of bioactive compounds that are used in the treatment of various diseases. Plant extracts are associated with various pharmacological activities like anticancer, anti-inflammatory, antimalarial and analgesic effects. Medicinal plants contain physiologically active principles that over the years have been exploited in traditional medicine for the treatment of various ailments [1]. Proven medicinal plants are used in treatment of diseases either alone or in combination with other plants. They are used as anti-infectious agents, anti-malarial, anti-tumor agents, laxatives, cardiovascular and nerve remedies [2]. Some biologically active plant-derived secondary metabolites have found application as drugs or as model compounds for drug synthesis and semi-synthesis [3].

Some secondary plant metabolites are used though in limited quantities, as pharmacological tools to study various biochemical processes [4]. Diterpene esters from latex of various *Euphorbia* species are examples of potent irritants and carcinogens, which are useful in studies of chemical carcinogenesis [3].

*Senna spectabilis* (L.) species belongs to the family Fabaceae and its common name is yellow shower (English). The species is recognized as one of the most popular and reliable stimulant laxatives. *Maytenus putterlickoides* (L.) is a shrub or small tree 1-3 (6) m high and belongs to the family Celastraceae. Decoction of the leaves may be mixed with soup and drunk for internal injuries, antiplasmodia and also for cancer or tumors [5].

*Olinia usambarensis* is also called *Olinia rochetiana* and belongs to the family Oliniaceae. Decoctions of the roots are drunk to cure fever. A decoction from the bark is drunk to cause emission of tapeworms, for rheumatism, bronchitis and indigestion [5]. The bark and leaves of *O. usambarensis* are used by traditional herbalists for treating a variety of ailments such as headaches, scabies and madness. It is also used to cure menstrual pain and intestinal worms [6]. Bark or roots are pounded,

water added and the resulting paste applied on swellings such as those on the throat and other tumors.

Inner bark may be pounded, mixed with *Brucea* spp and *Myrica salicifolia* and taken in a meat soup as a remedy for abscess, whooping cough and measles. In Kenya, the Taita people boil the bark in water and use it to treat a fatal childhood disease called 'nyago' characterized by strong muscular contractions, stomach pains and disturbed breathing, or it may be scraped and the resulting powder used to dress wounds. Malaria and backache are treated using juice obtained from roots that have been pounded and soaked in water [7].

Diarrhoea is a major cause of mortality and morbidity throughout the world and thus there is interest in the discovery of novel compound to treat this disease. Studies have validated the use of traditional antidiarrheal medicinal plants by investigating the therapeutic activity of these plants. These plants have been reported to have antispasmodic effects, stimulate water adsorption, suppress gut motility, delay intestinal transit and reduce electrolyte secretion.

Alkaloids, flavonoids, tannins and terpenes are some of the phytochemicals believed to be responsible for the antidiarrheal activity by increasing electrolyte and water reabsorption in the colon. These phytochemicals can however, be potentially toxic and thus there is need to evaluate the safety of the herbal preparations. This study aimed at evaluating the tolerability and safety of the herbal preparations of

\*Corresponding author: Francis Mugweru Gitau, Department of Biochemistry and Biotechnology, Kenyatta University, P.O. Box 43844-00100, Nairobi, Kenya, Tel: +254721236674; E-mail: [fgmugweru@yahoo.com](mailto:fgmugweru@yahoo.com)

Received March 21, 2016; Accepted May 04, 2016; Published May 11, 2016

Citation: Mugweru FG, Nyamai DW, Arika WM, Mworja JK, Ngugi MP, et al. (2016) In Vivo Safety of Aqueous Extracts of *Maytemus putterlickoides*, *Senna spectabilis* and *Olinia usambarensis* on Mice Models. J Clin Toxicol 6: 305. doi:10.4172/2161-0495.1000305

Copyright: © 2016 Mugweru FG, et al. This is an open-access article distributed under the terms of the Creative Commons Attribution License, which permits unrestricted use, distribution, and reproduction in any medium, provided the original author and source are credited.

*Maytenus putterlickoides* (A. Rich) *Olinia usambarensis* and *Senna spectabilis* (L.) Caesalpiniaceae.

## Material and Methods

### Collection of medicinal plants

The medicinal plants studied included *Maytenus putterlickoides* (A. Rich) Celastraceae, *Senna spectabilis* (L.) Caesalpiniaceae and *Olinia usambarensis* (Gilg.) Oliniaceae. They were collected from their natural habitats in Mbeere District, Embu county, Kenya. A botanist, Mr. Antony Mutiso from University of Nairobi, Department of Botany assisted in the identification and collection of plant materials with consideration of the bio-conservation aspects.

### *In vivo* single-dose toxicity testing

Experimental animals: Twenty (20) male Swiss albino mice (3-4 weeks old) that weighed an average of 18 g were used in the study. They were bred in the animal house at the Biochemistry and Biotechnology Department of Kenyatta University. The mice were housed at a temperature of 25°C with 12 h/12h darkness-light photoperiod cycles and fed on rodent pellets and water ad libitum. The mice were divided into four different groups of five mice each. One group served as the untreated control. The other three groups were treated with 1000 mg/kg body weight of the extracts.

The three extracts that were active against the diarrhea causing pathogenic bacteria in previous bioassay were subjected to *in vivo* toxicity tests. The three extracts were administered orally to each of the three groups accordingly on daily basis for a period of a month. Saline was administered to the fourth group as negative control. During this period, the mice were fed ad libitum to mice pellets and allowed free access to water. They were observed for any signs of general illness, change in behavior and mortality. At the end of one month the mice were sacrificed.

The body weight of each mouse was taken using an electronic beam balance model type BL-220H, (Shimadzu Corporation Japan) during the acclimatization period, before and after commencement of dosing, once weekly during the dosing period and on the day of sacrifice. On the day of sacrifice, the animals were euthanized by use of chloroform and later sacrificed [8]. Different organs namely the heart, liver, lungs, spleen, kidneys and testicles were carefully dissected out and weighed in grams. Necropsy samples were collected and stored in 10% formalin. The tissues were processed using the standard protocols of histopathology.

Histopathology: The formalin fixed organs were trimmed to include all major parts to be investigated and washed in running water overnight to remove excess formalin. The tissues were then processed using an automatic tissue processor [9]. The tissues were dehydrated sequentially in increasing concentrations (50, 70, 90, and absolute) of alcohol. Tissues were washed for 2 hr in 100% alcohol. The tissues were then cleared of alcohol twice in two changes of Xylene. Infiltration was done by passing them through molten paraffin wax for 6 hrs, 3 hr in each wax bath.

The tissues were embedded in fresh molten wax in embedding moulds. Embedded tissues were then attached to wooden block and sectioned at 0.5  $\mu$ m thicknesses with a microtome and floated in warm water bath at 54°C to spread out, then attached onto a clean microscopic slide. After holding in hot oven for 15 minutes, the tissue sections were dewaxed in Xylene and then stained with haematoxylin and eosin dyes using standard histological protocols. The stained tissues were cover

slipped with DPX mountant, dried and examined microscopically for any pathological changes.

Biochemical assays: At the end of the experimental period (4 weeks), all animals were exsanguinated and blood samples were drawn from the heart of each sacrificed animal. The samples were collected in plastic test tubes and allowed to stand for 3 hr to ensure complete clotting. The clotted blood samples were centrifuged at 3000 rpm for 10 min and clear serum samples were aspirated off and stored frozen at -20°C.

Sample analysis was done using the Olympus 640 chemistry auto analyzer (AU 640 OLYMPUS). This is a discrete, random access clinical analyzer capable of performing a wide range of chemistry tests in a single run. All reagents for the machine were commercially obtained to fit the required volumes and concentration. The reagents were in specific containers referred to as "reagent cartridges". The reagent cartridges were bar coded for the identification by the machine.

The machine was programmed for the selected tests for each sample. The sample sectors were then placed into the autoloader assembly. A number of events that occurred simultaneously were performed automatically under direct control of the instrument microprocessors. The analyzer was able to determine, activity of Aspartate Aminotransferase (AST), Alanine Aminotransferase (ALT), Alkaline Phosphatase (ALP), Blood Levels of Urea (BUN), Creatine Kinase (CK), Gamma-glutamyltransferase (-GT), Glucose (Glu), Uric acid (UA), Lactate dehydrogenase (LDH) and Urea compared with the quality control runs.

Determination of hematological parameters: Blood was examined using standard protocols [10]. Red blood cells, white blood cells, hemoglobin and mean hematocrit count were determined using the coulter count system Beckman Coulter® (Thermo Fisher, UK). The machine automatically dilutes a whole-blood sample of 30  $\mu$ l, lyses and counts and gives a print-out result of absolute numbers of white blood cells (WBC) (expressed as number of cells  $\times 10^9$  per liter) and red blood cells (RBC) number of cells  $\times 10^{12}$  per liter).

In addition Hb (in grams per liter) and MCHC (in grams per deciliter) were measured by the analyzer. The autoanalyser utilizes two independent methods. These methods are the independent method for determining the white blood cells [11], and the modified cyanomethaemoglobin method for determining the haemoglobin (International Committee for Standardization in Haematology, 1978).

Differential leucocytes counts for neutrophils, lymphocytes, basophils, eosinophils and monocytes were examined from stained blood films [10]. Air-dried thin blood films stained with giemsa stain were examined microscopically using magnification 400 and 1000 for differential WBC counts and cell morphologies respectively. Neutrophil (N), lymphocyte (L) and monocytes (M) absolute counts (number of cells  $\times 10^9$ ) per liter were obtained by expressing their percent differential counts against the total WBC absolute counts [10].

## Results

### *In vivo* single dose toxicity studies

Effects of oral administration of 1.0 g of medicinal plant extracts/kg body weight of mouse on weekly weight change for one month: Table 1 shows the effects of oral administration of aqueous plant extracts at 1.0 g/kg body weight of mouse. Results show that oral administration of *S. spectabilis* and *M. putterlickoides* increased the growth rate rapidly

Treatment	Weekly Weight of mice (g)					ΔWeight/Week (g/Week)
	0	1	2	3	4	
Control	17 ± 2	18.6 ± 2.14	20.7 ± 2.68	21.2 ± 2.49	22 ± 2.53	1.24 ± 0.30
<i>S. spectabilis</i>	17.6 ± 1.5	18.1 ± 2.13	18.6 ± 2.93	19.9 ± 2.95	20.2 ± 2.5	0.92 ± 0.48*
<i>M. putterlickoides</i>	17.8 ± 1.1	18.7 ± 0.66	20.1 ± 0.59	22.3 ± 1.48	24.2 ± 1.64	1.61 ± 0.72*
<i>O. usambarensis</i>	20.7 ± 0.8	19.5 ± 1.09	18.7 ± 1.12	19.5 ± 1.01	20.1 ± 0.87	-0.56 ± 0.15*

**Table 1:** The effects of oral administration of 1.0 g of medicinal plant extracts/kg body weight of mouse on weekly weight change for one month. Results are expressed as Mean ± SD for five mice per group. Difference between mean weekly change in body weight of the control mice and mice treated with each of the plant extracts was compared using the student's test. \*P<0.05 was considered statistically significant.

Treatment	Liver	Brain	Kidney	Lungs	Spleen	Testis	Heart
Control	6.27 ± 0.64	1.10 ± 0.07	1.02 ± 0.07	0.96 ± 0.13	0.81 ± 0.07	0.58 ± 0.02	0.30 ± 0.05
<i>S. spectabilis</i>	7.82 ± 2.65	1.50 ± 0.49	1.59 ± 0.45*	1.34 ± 0.50	1.24 ± 0.52*	0.71 ± 0.09	0.64 ± 0.20*
<i>M. putterlickoides</i>	6.24 ± 0.46	1.15 ± 0.22	1.38 ± 0.19*	0.98 ± 0.21	0.91 ± 0.11	0.86 ± 0.13*	0.51 ± 0.08*
<i>O. usambarensis</i>	8.24 ± 0.48*	1.62 ± 0.13*	1.73 ± 0.13*	1.40 ± 0.09*	1.39 ± 0.14*	0.66 ± 0.03	0.61 ± 0.06*

**Table 2:** Effects of administration of 1 g/kg body weight dose of aqueous medicinal plant extracts on percentage organ weights in mice after one month of treatment. Results are expressed as Mean ± SD for five mice per group. Differences between percentage mean of weight of individual organs of mice treated with each of the plant extracts and the control mice was compared using the students' test \*p<0.05 was considered statistically significant.

Hematological Parameters	Treatment			
	Control	<i>S. spectabilis</i>	<i>M. putterlickoides</i>	<i>O. usambarensis</i>
WBC (x10 <sup>9</sup> /μL)	11.28 ± 1.18	8.725 ± 1.44	9.5 ± 1.88	11.98 ± 1.70
RBC (x10 <sup>6</sup> /μL)	8.23 ± 1.08	8.05 ± 0.99	8.91 ± 0.9	7.25 ± 0.10
HGB (g/dL)	11.34 ± 0.60	11.05 ± 0.34	12.3 ± 1.28	9.86 ± 1.42
PCV (%)	58.7 ± 3.10	57.19 ± 3.92	63.36 ± 34	34.18 ± 4.19*
MCV (fL)	72.0 ± 6.13	69.13 ± 1.29	71.24 ± 47	47.4 ± 4.08*
MCH (pg)	13.96 ± 1.6	13.88 ± 1.44	13.82 ± 0.92	13.66 ± 1.50
MCHC (g/dL)	19.28 ± 0.83	19.38 ± 0.81	19.4 ± 0.29	28.8 ± 1.09*
PLT (x10 <sup>3</sup> /μL)	799.8 ± 127	863 ± 79	954.4 ± 158	613 ± 215
Ly (%)	81.94 ± 3.09	83.05 ± 1.76	85.54 ± 3.98	79.96 ± 0.98
RDW (%)	17.14 ± 1.69	18.25 ± 2.1	18.32 ± 2.77	16.42 ± 1.51
PCT (%)	0.41 ± 0.03	0.45 ± 0.04	0.57 ± 0.16	0.18 ± 0.06*
MPV (fL)	5.64 ± 0.91	5.25 ± 0.24	4.64 ± 2.58	3.22 ± 0.62*
PDW (%)	18.06 ± 0.61	18.28 ± 0.72	17.83 ± 1.26	17.84 ± 0.43

**Table 3:** Effects of oral administration of 1 g/kg body weight of medicinal plant extracts for one month on hematological parameters in mice. Results are expressed as Mean ± SD for five animals per group. Difference between mean hematological parameters of the control mice and mice treated with each of the plant extracts are compared using the students t test \*P<0.05 was considered statistically significant.

in third and fourth week relative to the control mice. *O. usambarensis* at 1.0 g/kg body weight dose in mice reduced their body weight in the second, third and fourth week relative to the control mice.

Effects of administration of 1 g/kg body weight dose of aqueous medicinal plant extracts on percentage organ weights in mice for one month: Table 2 shows the effect of oral administration of *S. spectabilis*, *M. putterlickoides* and *O. usambarensis* to mice at 1 g/kg body weight dose for one month on percent organ weights. Results show that *S. spectabilis* significantly increased the weight of the kidney, spleen and heart while *M. putterlickoides* increase the weight of kidney, testis and the heart. Results also show that *O. usambarensis* extract significantly increased the weight of the liver, brain, kidney, lungs, spleen and the heart.

Effect of oral administration of 1 g/kg body weight of medicinal plant extracts for one month on hematological parameters in mice: Table 3 shows the effect of oral administration of different plant extracts at 1 g/kg body weight dose of different extracts for one month on some end point hematological parameters in mice. Results show that oral administration of *O. usambarensis* aqueous extract to mice at 1 g/kg body for one month significantly decreased packed cell volume (PCV), mean cell volume (MCV), Plateletcrit (PCT), Mean platelet volume

(MPV) but an increase in Mean Cell Hemoglobin Concentration (MCHC) compared to the normal control.

Effects of oral administration of 1.0 g/kg body weight of different plant extract on differential white blood cell count (DLC) in mice: Table 4 shows the effect of oral administration of *S. spectabilis*, *M. putterlickoides* and *O. usambarensis* to mice at 1 g/kg body weight dose for one month on some differential white blood cell count (DLC) in mice. The results show that oral administration of *S. spectabilis* and *M. putterlickoides* significantly decreased neutrophils, eosinophils and monocytes count compared to those in the control mice. However oral administration of *O. usambarensis* extracts at the same dose for one month significantly increased the lymphocytes count compared to those in the control mice.

Effect of oral administration of 1 g/kg body weight of different plant extract for one month on biochemical parameters in mice: Table 5 shows the effect of oral administration of 1 g/kg body weight of different plant extract for one month on some end point biochemical parameters in mice. Results shows that oral administration of *S. spectabilis* extract significantly increased the levels of blood uric acid while *O. usambarensis* significantly increased aspartate aminotransferase activity (AST), Lactate dehydrogenase (LDH) and AST/ALT ratio.

Treatment (mg/kg/day)	Differential white blood cell count					
	WBC	Neutrophils	Lymphocytes	Eosinophils	Monocytes	Basophils
Control	11.28 ± 1.18	3.41 ± 0.45	5.79 ± 0.52	1.04 ± 0.14	0.97 ± 0.15	0.11 ± 0.01
<i>S. spectabilis</i>	8.73 ± 1.43	2.43 ± 0.34*	4.73 ± 0.89	0.87 ± 0.12*	0.65 ± 0.13*	0.10 ± 0.01
<i>M. putterlickoides</i>	9.20 ± 1.9	2.83 ± 0.54*	5.05 ± 1.07	0.86 ± 0.15*	0.64 ± 0.13*	0.09 ± 0.02
<i>O. usambarensis</i>	12.0 ± 1.7	3.26 ± 0.46	6.67 ± 1.01*	1.08 ± 0.17	0.91 ± 0.13	0.13 ± 0.01

**Table 4:** Effects of oral administration of 1 g/kg body weight of different plant extract on differential white blood cell count in mice. Results are expressed as Mean ± SD for five mice per group. Differences between Differential leucocytes count (DLC) of mice treated with each of the plant extracts and the control mice was compared using the students' t test \*p<0.05 was considered statistically significant. DLC is calculated by multiplying the percent of each white blood cell type by the total WBC count.

Parameter	ALT(U/L)	AST(U/L)	ALP (U/L)	UA (µmol/L)	LDH(U/L)	CK(U/L)	AST/ALT
Control	54.4 ± 17	266.2 ± 34	21.6 ± 18	151.8 ± 20	3999 ± 203	621.6 ± 213	5.38 ± 1.83
<i>S. spectabilis</i>	35.5 ± 17	215 ± 34	4.5 ± 18	283 ± 20*	3844 ± 203	321 ± 213	7.6 ± 1.82*
<i>M. putterlickoides</i>	36 ± 4.11	244 ± 94	3.75 ± 6.7	138 ± 74	3539 ± 2471	652 ± 99	7.0 ± 3.56*
<i>O. usambarensis</i>	45 ± 9.7	542 ± 207*	9.4 ± 21	174 ± 61	4576 ± 474*	578 ± 63	11.0 ± 3.53*

**Table 5:** Effects of oral administration of 1 g/kg body weight of different plant extract for one month on biochemical parameters in mice. Results are expressed as Mean ± SD for five animals per group. Difference between mean of the measured biochemical parameters of the control mice and mice treated with each of the plant extracts was compared using the student's t test. \*P<0.05 was considered statistically significant.

## Histopathology

Histopathological examination of liver, kidney and intestine specimens from normal mice and mice orally treated with 1 g/kg body weight/day of the most active medicinal plant extract for 30 days are shown on the Figures below.

### The liver

The observed normal liver of mouse treated with normal saline for 30 days shows intact hepatocytes, clear veins and sinusoid as show with the arrow in (Figure 1). Liver specimen from mice treated orally with *M. putterlickoides* and *O. usambarensis* (1 g/kgbw/day) for 30 days show intact hepatocytes, normal uncongested central veins and sinusoids. Liver specimen from mice treated orally with *Olinia usambarensis* (1 g/kgbw/day) for 30 day revealed liver infiltration and venous congestion (Arrow, Figures 2-4).

### Kidney

Kidney of a mouse orally treated with normal saline and those treated orally with an aqueous extract of *M. putterlickoides* (1 g/kgbw/day) for 30 days show Normal epithelium and glomerulus (respectively Figures 5 and 6). However kidney of a mouse orally treated with an aqueous extract of *Senna spectabilis* and *O. usambarensis* (1 g/kgbw/day) for 30 days show intense infiltration of inflammatory cells causing necrosis and loss of cellular details (Arrow Figures 7 and 8).

### Intestine

Intestine of a mouse orally treated with normal saline, and *M. putterlickoides* (1 g/kgbw/day) for 30 days showed the normal structure of villi (well aligned with cells). Intestines of a mouse orally treated with an aqueous extract of *S. spectabilis* and *O. usambarensis* (1 g/kgbw/day) for 30 days revealed Villi disintegration and lack of continuity of the villi coating (Figures 9-12).

## Discussion

The toxicity of the active plants extracts against the bacterial isolates was assessed to ascertain whether they are suitable for therapeutic purposes without causing poisoning to the host cells. The white blood cell differential count is often used as part of a complete blood count (CBC) as a general health check. It may be used to help diagnose the cause of a high or low white blood cell (WBC) count, as determined with a CBC. It may also be used to help diagnose and/or monitor other

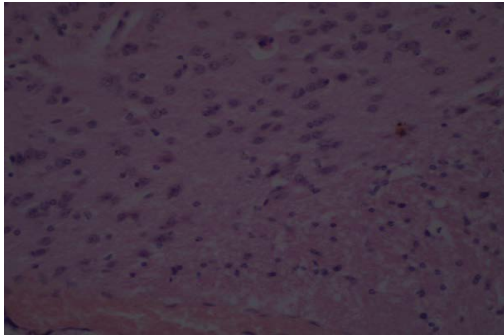
diseases and conditions that affect one or more different types of WBCs. The low level of neutrophils, eosinophils and monocytes in mice treated with 1g of *S. spectabilis* and *M. putterlickoides* per kg body weight, compared to the control shows the mice reacted to the plant extract. The reduction in these types of white blood cells, when plant extracts of *S. spectabilis* and *M. putterlickoides* were administered orally, may imply a reduction in the ability of the body to respond to infection [12]. This can be explained by the abnormal increase in size of the spleen thus affecting the lymphoid follicles which contain B lymphocytes and lymphoid populations. Lymphoid depopulation/lymphoid follicle reduction could be caused by the presence of cytotoxic saponins which destroy the lymphocytes. Similar toxicity pattern was observed from histopathological changes due to saponin in mice [13].

The significant increase in lymphocytes observed on oral administration of plant extracts of *O. usambarensis* indicates a more accelerated production of these cells and a boosted immunity to mice by these extracts [12]. The increased lymphocytes (main effectors cells of the immune system) indicate a possible stimulatory effect by these extract on lymphocytes production [14]. This could be due to tissue damage caused by some constituents of the plants extracts. This argument is in line with the observed enlargement of the liver, brain, kidney, lung, spleen and Heart of mice orally administered with 1 g of *O. usambarensis* extracts/kg body weight. The fact that oral administration of *O. usambarensis* extract did not increase white blood cell count might imply that biotransformation of this extract components may be essential for this effect to be expressed.

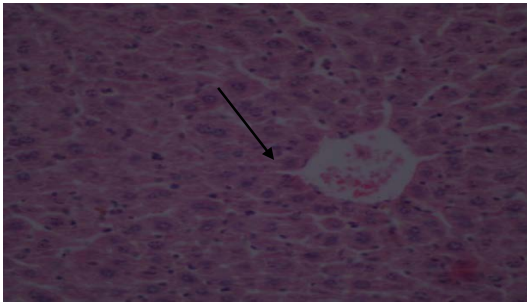
Body weight maintenance can be achieved through manipulation of energy expenditure (EE), mainly heat production also known as thermogenesis, appetite suppression/satiety enhancement, fat and glucose absorption blocking. Either one or more components can be altered by the phytochemicals. Most phytochemicals that affect body weight regulation have a complex mechanism of action, where their main effect is increase or decrease body weight. The site of main mechanism of action includes central nervous system (CNS), peripheral or both.

Some free fatty acids (FFA) significantly increase the release of satiety hormones such as cholecystokinin (CCK) [15]. CCK delays gastric emptying and produces a subsequent increased feeling of satiety and a decreased appetite. In terms of inducing satiety-hormone secretion, long chain fatty acids are more effective than medium

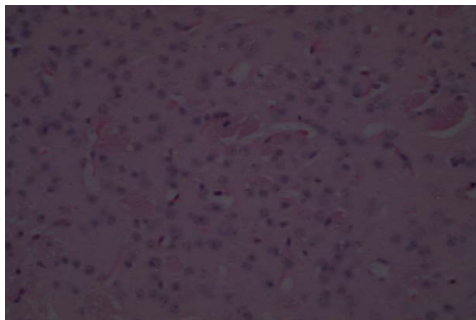




**Figure 1:** Photo-micrograph of a histological section of a liver of a mouse orally treated with normal saline, for 30 days. Note: intact hepatocytes, normal uncongested central veins and sinusoids Haematoxylin and eosin stain Mg 400X.



**Figure 2:** Photo-micrograph of a histological section of a liver of a mouse orally treated with an aqueous extract of *Olinia usambarensis* (1 g/kgbw/day) for 30 days Note: intact hepatocytes, congested central veins and sinusoids (Arrow). Haematoxylin and eosin stain Mg 400X.

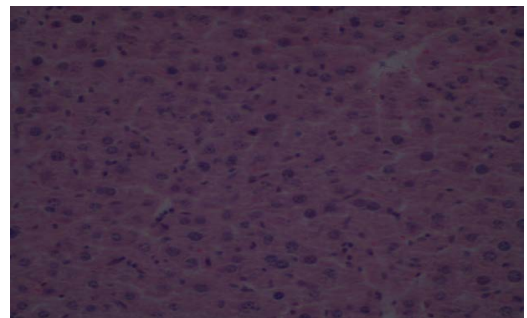


**Figure 3:** Photo-micrograph of a histological section of a liver of a mouse orally treated with an aqueous extract of *M. putterlickoides* (1 g/kgbw/day) for 30 days Note: intact hepatocytes, normal uncongested central veins and sinusoids. Haematoxylin and eosin stain Mg 400X.

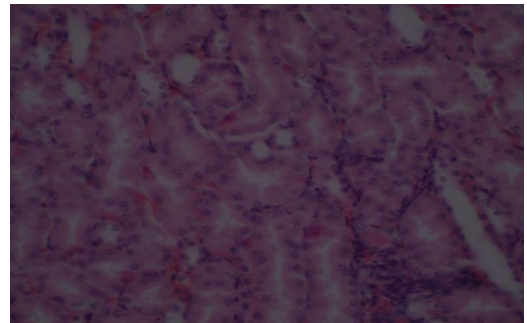
chain fatty acids. Also Poly unsaturated Fatty acids (PUFAs) are more effective than Mono unsaturated fatty acids (MUFAs) [16].

Alkaloids such as p-octopamine and synephrines which exert adrenergic agonist activity aid weight loss. Synephrines potentially increase Energy Expenditure (EE) and decrease food intake. In addition, there is some evidence those adrenergic agonists, decrease gastric motility [17]. Alkaloid test was positive in all the plant extracts but was strongly positive in *O. usambarensis* which show a remarkable decrease of the mice body weight after administration of 1 g of plant extract per kg body for one month.

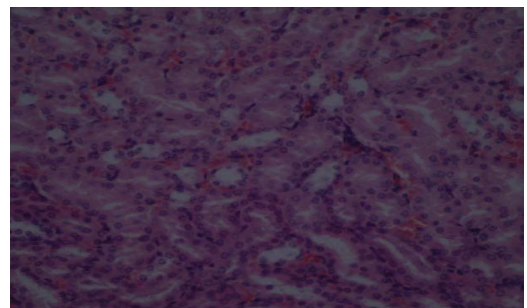
Flavone glycosides, saponins and various other flavonoids have appetite suppressant action that has peripheral and central effects. In the adipose tissue, glycosides reduce lipogenesis [18]. In the central structures regulating appetite, glycosides and its related molecules have mechanism where they act by amplifying the signaling of the energy sensing function in the hypothalamus [19]. The reduced growth rate in animals treated with *O. usambarensis* extract relative to that of control, may also be due tannins. Tannins reduce feed intake by decreasing palatability and reducing feed digestion. Tannins reduce palatability because they are astringent. Astringency is the sensation caused by the formation of complexes between tannins and salivary



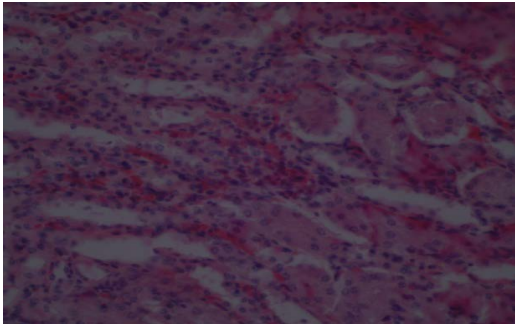
**Figure 4:** Photo-micrograph of a histological section of a liver of a mouse orally treated with an aqueous extract of *S. spectabilis* (1 g/kgbw/day) for 30 days Note: intact hepatocytes, normal uncongested central veins and sinusoids. Haematoxylin and eosin stain Mg 400X.



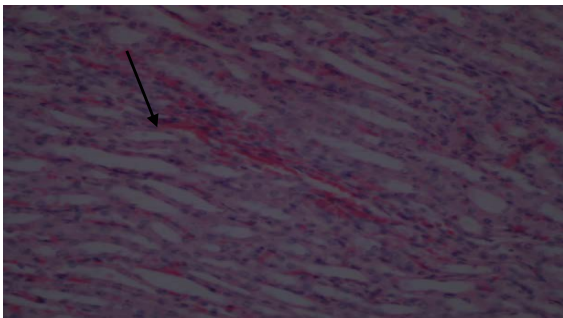
**Figure 5:** Photo-micrograph of a histological section of a kidney of a mouse orally treated with normal saline, food and water for 30 days. Note: Normal epithelium and glomerulus. Haematoxylin and eosin stain. Mg 400X.



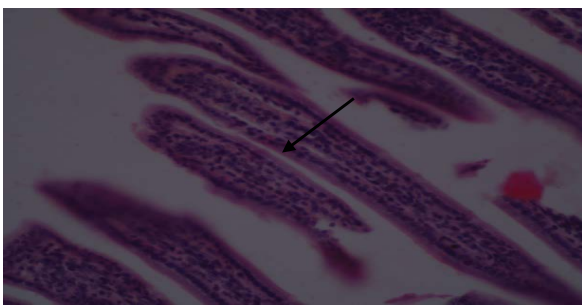
**Figure 6:** Photo-micrograph of a histological section of a kidney of a mouse orally treated with an aqueous extract of *M. putterlickoides* (1 g/kgbw/day) for 30 days Note: Normal epithelium and glomerulus. Haematoxylin and eosin stain Mg 400X.



**Figure 7:** Photo-micrograph of a histological section of a kidney of a mouse orally treated with an aqueous extract of *S. spectabilis* (1 g/kgbw/day) for 30 days Note: There intense infiltration of inflammatory cells causing necrosis and loss of cellular details (Arrow). Haematoxylin and eosin stain Mg 400X.



**Figure 8:** Photo-micrograph of a histological section of a kidney of a mouse orally treated with an aqueous extract of *O. usambarensis* (1 g/kgbw/day) for 30 days Note: There intense infiltration of inflammatory cells causing necrosis and loss of cellular details (Arrow) Haematoxylin and eosin stain Mg 400X.



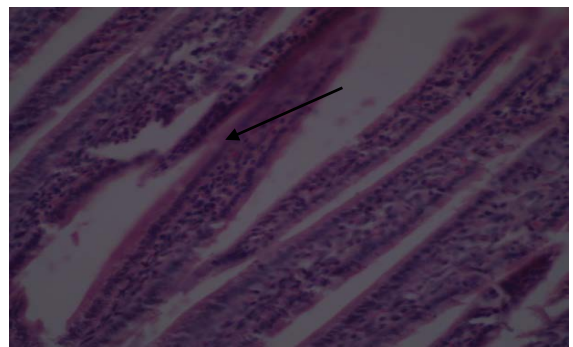
**Figure 9:** Photo-micrograph of a histological section of intestine of a mouse orally treated with normal saline, food and water for 30 days. Note: the normal structure of villi (well aligned with cells) (Arrow). Haematoxylin and eosin stain. Mg 400X.

glycoprotein. Low palatability results in reduced feed intake hence poor performance. Reduced digestibility influence feed intake negatively because of the filling effect associated with undigested feedstuff.

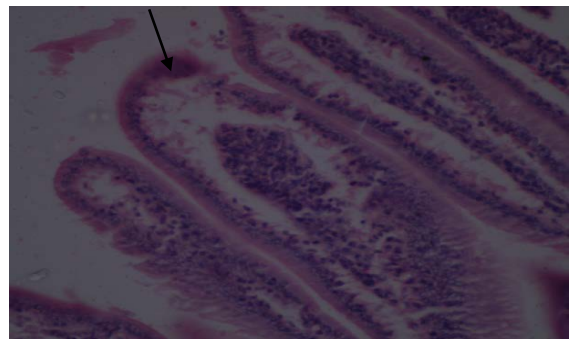
Tannins are classified into hydrolysable and condensed tannins. Hydrolysable tannins are converted by microbial metabolism and gastric digestion into absorbable low molecular weight metabolites such as tannic acid which are toxic. The major lesions associated with hydrolysable tannins poisoning are hemorrhagic gastroenteritis which decreases absorption of nutrients, necrosis of the liver and kidney damage with proximal tubular necrosis. Hemorrhagic gastroenteritis

was confirmed histologically by the infiltration of villus stroma by more inflammatory cells and minimal oedema of the intestines of animal administered with 1 g of *O. usambarensis* extract/kg body weight. Villi disintegration was also observed and there was no continuity of the villi coating.

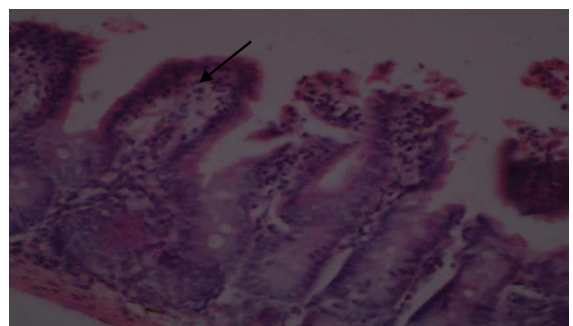
The condensed tannins like protanthocyanidins (PAs) retard growth by inhibiting feed intake and digestibility [20]. Protanthocyanidins which are not absorbed by the digestive tract, damage the mucosa of the gastrointestinal tract, decreasing the absorption of nutrients such as proteins, carbohydrates and essential amino acids such as methionine



**Figure 10:** Photo-micrograph of a histological section of intestine of a mouse orally treated with an aqueous extract of *S. spectabilis* (1 g/kgbw/day) for 30 days Note: the normal structure of villi (well aligned with cells) (Arrow). Haematoxylin and eosin stain Mg 400X.



**Figure 11:** Photo-micrograph of a histological section of intestines of a mouse orally treated with an aqueous extract of *S. spectabilis* (1 g/kgbw/day) for 30. Note: Villi disintegration and lack of continuity of the villi coating (Arrow). Haematoxylin and eosin stain Mg 400X.



**Figure 12:** Photo-micrograph of a histological section of intestines of a mouse orally treated with an aqueous extract of *O. usambarensis* (1 g/kgbw/day).



and lysine. They also increase excretion of proteins and essential amino acids as well as altering the excretion of certain cations. This reduced body weight in extract treated animals could also be partly explained by the increase in weight of the kidney, spleen and heart in animals treated with *S. spectabilis* and *M. putterlickoides*. Animals treated with *O. usambarensis* had an increase in weight of all the examined organs except the testis.

Organ weights are widely accepted in the evaluation of samples associated with toxicity [21,22]. Organ weight changes are often associated with treatment related effects. The STP recommends that liver, heart, kidneys, brain, adrenal glands, and testes (preferably from sexually mature animals) should be weighed in all species in multidose general toxicology studies of 7 days to 1 year in duration. Alterations in liver weight may suggest treatment-related changes including hepatocellular hypertrophy (e.g., enzyme induction or peroxisome proliferation) [23,24]. Liver weights may be elevated in studies of less than 7 days duration for potent hepatic enzyme-inducing compounds. Elevated heart weight may be the only evidence of myocardial hypertrophy that is often macroscopically and microscopically difficult to recognize [23,25]. Changes in kidney weight may reflect renal toxicity, tubular hypertrophy or chronic progressive nephropathy [23]. Changes in brain weights are rarely associated with neurotoxicity. The utility of brain weight rests in the ability to calculate organ to brain weight ratios. Some consider evaluation of organ to brain weight ratios helpful when terminal body weights are affected by the samples tested or to normalize organ weight data when there is large inter-animal variability. Changes in testes weights may reflect changes in seminiferous tubules or interstitial edema. Changes in epididymal weight may be a sensitive indicator of decreased sperm production or may reflect edema or inflammation [26]. Organ weight changes might represent secondary effects of treatment on the reproductive cycle rather than a direct toxic effect of the sample on test.

The liver of all the mice treated with *S. spectabilis* and *M. putterlickoides* plant extract had intact hepatocytes, uncongested central veins and sinusoids. However liver of a mice orally treated with an aqueous extract of *O. usambarensis* (1 g/kgbw/day) for 30 days revealed intact hepatocytes, congested central veins and sinusoids, inflammation around blood vessel and damage at specific points. Histological section of a kidney of a mouse orally treated with an aqueous extract of *S. spectabilis* and *O. usambarensis* (1 g/kgbw/day) for 30 days also revealed intense infiltration of inflammatory cells causing necrosis and loss of cellular details.

The level of Lactate dehydrogenase (LDH), Aspartate aminotransferase (AST) and Alanine aminotransferase (ALT) ratio were high. LDH is an enzyme found in cells of many body tissues including the heart, liver, kidney, skeletal muscle, brain, Red blood cells and lungs. It is responsible for converting Muscle lactic acid to pyruvic acid, an essential step in producing cellular energy. High level of LDH in blood indicates tissue damage. However isoenzyme tests are better indicators of the specific organ or tissue damage. AST is found in muscle cells apart from liver cells. ALT is found solely in the liver cells and is useful in detecting liver diseases. The elevated or raised levels of both the enzymes AST and ALT is an indicator of liver damage and is measured together as part of liver function panel to detect liver damage. Liver diseases in which AST is higher than ALT including alcohol induced liver damage, cirrhosis and liver tumor [27]. The plant extract administered to mice at 1 g/kg body weight damage the liver and other body organs. This is in agreement with the increase in size of all the organs except the

testis (*O. usambarensis*), increase in size of the kidney, spleen and heart (*S. spectabilis*) and increase in size of kidney, testis and heart (*M. putterlickoides*). This is also supported by the high AST: ALT ratio in all the mice treated with the three plant extracts.

Oral administration of a high dose of *O. usambarensis* plant extracts caused microcytic hypochromic anemia. These abnormal blood conditions could be caused by toxic constituents in the plant extract including among others alkaloids saponins, flavanoids and tannins present in these extracts. These extract constituents could be reducing the erythron parameters [28]. Saponins hemolyse and cause cell death in many tissues [29]. Alkaloids have been shown to cause liver megalocytosis, proliferation of biliary tract epithelium, liver cirrhosis and nodular hyperplasia [30]. Terpenoids have been shown to increase membrane permeability to divalent and monovalent ions [30]. The trace elements copper and zinc which could also cause toxicity if taken at higher levels were present in levels below the recommended daily allowances. The extract constituents could also cause deficiency of folate through interfering with its absorption or making it biologically unavailable.

Hyperchromic anaemia as indicated by high level of MCHC is caused by abnormal concentration of haemoglobin which could be due to over production of immature reticulocyte from the bone marrow. This interfere with hemoglobin incorporation in these cells which are larger in size than mature cells resulting in decreased blood flow and poor tissue oxygenation (tissue hypoxia). Tissue hypoxia could be the cause of the increased of organs size. These abnormal tissue sizes could account for increased levels of biochemical parameters such aspartate aminotransferase and AST: ALT ratio after thirty days treatment with 1 g/kg body weight of each of the three plant extracts. Low levels of oxygen causes most tissues such as kidney, liver, heart, brain and testis to initially enlarge and as the swollen cells continue rupturing, the organ size reduces (organ atrophy).

## Conclusion

Phytochemicals have effects in the hematological and histopathological parameters of model animals and thus the safety of plant extracts should be evaluated before they are used in the treatment of diseases. Oral administration of 1 g/kg body weight of *O. usambarensis* (roots) extract to mice on daily basis for one month demonstrated some toxicological effects as evidenced by changes in hematological, biochemical, body weight, organ weights and histological indices. The reduced body weight could be as a result of reduced absorption of nutrients due to phytochemicals present in the extract.

## References

1. Evans CE, Banson A, Samuel OA (2002) Efficacy of some nupé medicinal plants against *Salmonella typhi*: an in vitro study. *J Ethnopharmacol* 80: 21-24.
2. Nwachukwu MI, Duru MKC, Amadi BA, Nwachukwu IO (2014) Comparative Evaluation of Phytoconstituents, Antibacterial Activities and Proximate Contents of Fresh, Oven Dried Uncooked and Cooked Samples of *Buchholzia coriacea* Seed and Their Effects on Hepatocellular Integrity. *Int J Pharma Sci Invent* 3: 41-49.
3. Edema MO, Alaga TO (2012) Comparative evaluation of bioactive compounds in *Hibiscus sabdariffa* and *Syzygium samarangense* juice extracts. *Afr Crop Sci J* 20: 179-188.
4. Srinivasan D, Nathan S, Suresh T, Lakshmana Perumalsamy P (2001) Antimicrobial activity of certain Indian medicinal plants used in folkloric medicine. *J Ethnopharmacol* 74: 217-220.
5. Kokwaro JO (1993) Medicinal plants of east Africa. Nairobi: Kenya Literature Bureau 401p. ISBN, 9966: 190.

6. Woodcock KA (1995) Indigenous knowledge and forest use. Two case studies from the East Usambaras, Tanzania- East Usambara catchment for project technology paper. Beekeeping Division and Finnish for park service, Daresalam and Vantage p 51.
7. Mbuya LP, Kajembe G, Mwenduwa M (1994) Useful trees and shrubs for Tanzania: Identification, Propagation and Management for Agricultural and Pastoral Communities. Regional Soil Conservation Unit (RSCU), Swedish International Development Authority (SIDA).
8. Hard GC, Iatropoulos MJ, Jordan K, Radi L, Kaltenberg OP, et al. (1993) Major difference in the hepatocarcinogenicity and DNA adduct forming ability between toremifene and tamoxifen in female Crl: CD (BR) rats. *Cancer Res* 53: 4534-4541.
9. Warmington AR, Wilkinson JM, Riley CB (2000) Evaluation of ethanol-based fixatives as a substitute for formalin in diagnostic clinical laboratories. *J Histotechnol* 23: 299-308.
10. Hippel TG (2007) Routine testing in hematology. *Hematology: clinical principles and applications*, (3rd eds.) St. Louis, MO: Saunders/Elsevier 160-174.
11. Clark KS, Hippel TG (2015) Manual, Semiautomated, and Rodak's Hematology: Clin Princ Appl 187.
12. Kaushansky K (1995) Thrombopoietin: the primary regulator of megakaryocyte and platelet production. *Thromb Haemost* 74: 521-525.
13. Diwan FH, Abdel-Hassan IA, Mohammed ST (2000) Effect of saponin on mortality and histopathological changes in mice. *East Mediterr Health J* 6: 345-351.
14. McKnight DC (1999) *Human Physiology*. (4th Eds.) Churchill Livingstone 290-294.
15. Pasman WJ, Heimerikx J, Rubingh CM, van den Berg R, O'Shea M, et al. (2008) The effect of Korean pine nut oil on in vitro CCK release, on appetite sensations and on gut hormones in post-menopausal overweight women. *Lipids Health Dis* 7: 10.
16. Lawton CL, Delargy HJ, Brockman J, Smith FC, Blundell JE (2000) The degree of saturation of fatty acids influences post-ingestive satiety. *Br J Nutr* 83: 473-482.
17. Astrup A (2000) Thermogenic drugs as a strategy for treatment of obesity. *Endocrine* 13: 207-212.
18. Preuss HG (2004) Effects of a natural extract of hydroxycitric acid (HCA-SX) and a combination of HCA-SX plus niacin bound chromium and Gymnema sylvestre extract on weight loss. *Diabetes Obes Metab* 6: 171-180.
19. Tucci SA (2010) Phytochemicals in the control of human appetite and body weight. *Pharmaceuticals* 3: 748-763.
20. Chung KT, Wong TY, Wei CI, Huang YW, Lin Y (1998) Tannins and human health: a review. *Crit Rev Food Sci Nutr* 38: 421-464.
21. Black H (2002) Preparation of the report for a toxicology/pathology study. *Handbook of Toxicologic Pathology* (W. M. Haschek, C. G. Rousseaux, and M. A. Wallig, editors), 1: 419-33.
22. Harwood M, Danielewska-Nikiel B, Borzelleca JF, Flamm GW, Williams GM, et al. (2007) A critical review of the data related to the safety of quercetin and lack of evidence of in vivo toxicity, including lack of genotoxic/carcinogenic properties. *Food Chem Toxicol* 45: 2179-2205.
23. Greaves P (2000) *Histopathology of Preclinical Toxicity Studies: Interpretation and Relevance in Drug Safety Evaluation*, (2nd Eds.) Elsevier Science, Amsterdam.
24. Amacher DE, Schomaker SJ, Boldt SE, Mirsky M (2006) The Relationship among Microsomal Enzyme induction, Liver weight and histological change in Cynomolgus Monkey toxicology studies. *Food Chem Toxicol* 44: 528-537.
25. Sellers RS, Mortan D, Michael B, Roome N, Johnson JK, et al. (2007) Society of Toxicologic Pathology position paper: organ weight recommendations for toxicology studies. *Toxicol pathol* 35: 751-755.
26. Creasy DM, Foster PM (2002) *Handbook of Toxicologic Pathology, Male reproductive system*, editors Haschek WM, Rousseaux CG, Wallig MA (Academic Press, San Diego, CA), 2,785-2846.
27. Pagana K, Pagana T (1998) *Manual of Diagnostic and Laboratory Tests*. (3rd Eds.) St. Louis: Mosby Elsevier; 2006, 409-412, 447-448.
28. Barger AM (2003) The complete blood cell count: a powerful diagnostic tool. *Vet Clin North Am Small Anim Pract* 33: 1207-1222.
29. Huhman DV, Berhow MA, Sumner LW (2005) Quantification of saponins in aerial and subterranean tissues of *Medicago truncatula*. *J Agric Food Chem* 53: 1914-1920.
30. Zeinsteger P, Romero A, Teibler P, Montenegro M, Rios E (2003) Toxicity of volatile compounds of *Senecio grisebachii* baker (margarita) flowers, in mice. *Revistade Investigaciones Agropecuarias* 32: 125-136.

**Citation:** Mugweru FG, Nyamai DW, Arika WM, Mworio JK, Ngugi MP, et al. (2016) *In Vivo* Safety of Aqueous Extracts of *Maytemus putterlickoides*, *Senna spectabilis* and *Olinia usambarensis* on Mice Models. *J Clin Toxicol* 6: 305. doi:[10.4172/2161-0495.1000305](https://doi.org/10.4172/2161-0495.1000305)

#### OMICS International: Publication Benefits & Features

##### Unique features:

- Increased global visibility of articles through worldwide distribution and indexing
- Showcasing recent research output in a timely and updated manner
- Special issues on the current trends of scientific research

##### Special features:

- 700+ Open Access Journals
- 50,000+ editorial team
- Rapid review process
- Quality and quick editorial, review and publication processing
- Indexing at major indexing services
- Sharing Option: Social Networking Enabled
- Authors, Reviewers and Editors rewarded with online Scientific Credits
- Better discount for your subsequent articles

Submit your manuscript at: <http://www.omicsonline.org/submit>